

Mersilene Mesh Vs Autogenous Fascia Lata for Upper Lid Sling Procedure

Hossein Salour, MD; Maryam Ale-Taha, MD; Abbas Bagheri, MD

Shaheed Beheshti Medical University, Tehran, Iran

Purpose: To compare mersilene mesh and autogenous fascia lata for upper lid sling procedure in the management of ptosis with poor levator function.

Methods: This randomized clinical trial included 9 patients with unilateral and 11 patients with bilateral congenital ptosis and poor levator function. All subjects underwent upper lid sling procedure with a random choice of two different materials: mersilene mesh in 16 eyelids and autogenous fascia lata in 15 eyelids.

Results: Overall, 31 eyelids underwent the upper lid sling procedure. There was no difference between the two groups in terms of final functional (lid fissure height stability) and cosmetic (lid margin contour) results. Dermatochalasis was more common in the fascia lata group (10 eyes) compared to the mersilene mesh group (2 eyes). Mersilene mesh extrusion occurred in two eyelids.

Conclusion: Mersilene mesh has favorable long-term functional results and a low rate of complications. This material may be considered as an alternative to autogenous fascia lata for frontalis suspension surgery.

Iran J Ophthalmic Res 2007; 2 (2): 135-140.

Correspondence to: Hossein Salour, MD. Associate Professor of Ophthalmology; Ophthalmic Research Center, Labbafinejad Medical Center, Boostan 9 St., Pasdaran Ave., Tehran 16666, Iran; Tel: +98 21 22585952, Fax: +98 21 22590607, e-mail: hosalour@hotmail.com

INTRODUCTION

Blepharoptosis is a relatively common condition which may present at birth or develop later during life. Ptosis surgery is one of the most common oculoplastic procedures with a choice of different techniques; in cases with poor levator function, the upper lid sling operation is the procedure of choice.^{1,2} Most oculoplastic surgeons prefer to use autogenous fascia lata for frontalis suspension because of the acceptable lid contour and favorable long-term outcomes.¹⁻³ Certain limitations in using autogenous fascia lata have led to the use of alternative materials, of which mersilene mesh seems to entail better long-term results in maintaining

eyelid contour while avoiding problems associated with use of fascia lata.⁴⁻¹¹

The present study was undertaken to compare the results and complications of upper lid sling procedure using autogenous fascia lata vs mersilene mesh in terms of eyelid crease symmetry, eyelid contour and lid fissure height.

METHODS

All patients with unilateral or bilateral upper lid ptosis who were referred to the oculoplastic service at Labbafinejad Medical Center from August 2003 to August 2005 and fulfilled the study criteria were randomly allocated to mersilene mesh and fascia lata for upper lid sling

material. Inclusion criteria were weak (<4 mm) levator function and age ≥ 3 years. Exclusion criteria included weak Bell's phenomenon (<2+), presence of jaw winking phenomenon, positive phenylephrine test, and disorders associated with secondary ptosis or ocular disorders other than ptosis such as myasthenia gravis, myotonic dystrophy, dysthyroid ophthalmopathy, blepharophimosis and chronic progressive extraocular ophthalmoplegia as well as history of extraocular or eyelid scars or tumors.

Preoperatively, all patients underwent a comprehensive ophthalmologic examination including determination of visual acuity, cyclorefraction, slitlamp biomicroscopy with special attention to the lacrimal meniscus, tonometry, funduscopy, pupillary reactions, evaluation of ocular motility and corneal sensation. Ptosis examination included eyelid crease height, lid fissure height (distance between the upper and lower lid margin centers in mm) in primary gaze and with inhibition of frontalis muscle function, levator muscle function (in mm), upper lid margin-reflex distance (MRD-1, distance between upper lid margin center and pupil light reflex in mm), lower lid margin-reflex distance (MRD-2, distance between lower lid margin center and pupil light reflex in mm), lagophthalmos, scleral show and Bell's phenomenon (ranging from 4+ implying complete disappearance of the cornea underneath the upper lid to zero corresponding to complete absence of Bell's phenomenon).

MRD-1, MRD-2 and lid fissure height were measured one and six weeks and six months postoperatively. Photography was performed preoperatively and repeated six weeks and three and six months postoperatively for evaluation of upper lid contour and symmetry. Postoperative complications such as corneal surface disorders, over-correction, under-correction and granuloma formation were also evaluated. Data was analysed using paired and unpaired *t*-tests for comparing mean values within and between the two groups, respectively with significance set at $P < 0.05$.

Surgical Technique

Mersilene Mesh Group

Three incisions were made above the brow in skin and subcutaneous tissues to reach the frontal periosteum using a #15 scalpel. The medial incision was made on the outer side of an imaginary line perpendicular to the medial canthus and the lateral incision was made on the outer side of an imaginary line perpendicular to the lateral canthus. After placing a lidplate for protection of the globe, three incisions were made on the upper lid 2 mm above the lid margin reaching the tarsus; the middle one in the central upper lid and the other two 5 mm on either side. Two bands of mersilene mesh measuring 15 cm in length and 5-7 mm in width were used for stringing using Wright needle as shown in figure 1. The free ends of the mesh were tied at the sites of medial, central and lateral incisions above the brow. After adjustment of eyelid height at the superior limbus, the knots were sutured with 5-0 Prolene and buried in the frontalis muscle and the skin was sutured with 5-0 Prolene.

Fascia Lata Group

With the knee and hip in semiflexion on one side, the whole leg was rotated medially such that the heel was positioned laterally. The thigh was then fixed with leukoplast adhesive to both sides of the surgical table while a pillow was placed under the hip and another between the knees. After preparation with povidone-iodine and draping, a 15 cm incision was made in the skin and subcutaneous tissues on the lateral thigh using a #15 scalpel starting 2.5 inch above the lateral femoral condyle extending toward the anterior superior iliac spine. Subcutaneous tissues were dissected using surgical scissors reaching fascia lata, a whitish glittering tissue. A strip of fascia, 10-15 cm in length and 0.5-1 cm in width (0.5 cm for unilateral and 1 cm for bilateral cases) was harvested using #15 scalpel and surgical scissors. Subcutaneous tissue was repaired using separate 2-0 vicryl sutures and

the skin was repaired with 4-0 nylon or Prolene sutures. The fascia strip was cleaned from unwanted tissues using surgical scissors and cut into strips 2-3 mm in width. The rest of the surgical procedure was similar to the mersilene mesh group.




Figure 1 Schematic presentation of the stringing procedure

After completion of the procedure in both groups, a 4-0 silk frost suture was inserted in the center of the lower lid and the eye was patched with gentamicin ointment for 6 hours. The patients received oral cephalexin 100 mg/kg for five days. The frost suture was removed after 24 hours in the absence of corneal epithelial defects, otherwise simple eye ointment was prescribed every 6-8 hours and removal of the frost suture was deferred until complete healing of the corneal epithelial defect.

RESULTS

This randomized clinical trial included 31 eyelids of 20 subjects including 9 patients with unilateral and 11 patients with bilateral blepharoptosis and poor levator function. Upper lid sling procedure was performed using mersilene mesh in 16 eyelids of 10 patients (8 male and 2 female) and autogenous fascia lata

in 15 eyelids of 10 patients (6 male and 4 female). Mean age was 15.7 ± 12.6 (range 3-42) years vs 14.1 ± 8.6 (range 3-26) years in the mersilene mesh and fascia lata groups, respectively. Mean follow-up period was 14.2 ± 0.59 (range 6-26) months and 15.1 ± 6.80 (range 9-29) months in the mersilene mesh and fascia lata groups, respectively. The two groups were comparable regarding age, sex and follow-up period.

Mean pre- and postoperative lid fissure height was 4.6 ± 1.6 and 8.6 ± 0.8 mm in the mersilene mesh group ($P < 0.001$) versus 6.4 ± 1.7 and 9.5 ± 0.6 mm in the fascia lata group ($P < 0.001$), respectively. Mean increase in lid fissure height in the mersilene mesh group (4.0 ± 1.5 mm) did not differ from that in the fascia lata group (3.1 ± 1.7 mm) ($P = 0.14$). Mean MRD-1 increase was 3.0 ± 1.5 mm in the mersilene mesh group and 2.9 ± 1.4 mm in the fascia lata group ($P = 0.027$). Changes in MRD-1 were statistically significant in both groups ($P < 0.04$).

Short-term (within two weeks) postoperative complications included punctate epithelial corneal erosions in three (18.75%) eyes and mersilene mesh exposure at the skin incisions in two (12.5%) eyelids in the mersilene mesh group. In comparison, punctate epithelial erosions and corneal epithelial defects occurred in seven (46.6%) eyes and entropion developed in two (13.3%) eyelids in the fascia lata group. Long-term (after two weeks) postoperative complications included under-correction in three (18.75%) eyelids (<1 mm in two eyelids and 1-2 mm in one eyelid) in the mersilene mesh group and under-correction and over-correction (<1 mm) each in one eyelid (6.7%) in the fascia lata group. At final follow-up, the eyelid fissure was stable in all eyes except one case (6.25%) of under-correction of 1 mm in the mersilene mesh group. Ten eyelids (66.7%) in the fascia lata group and two (12.5%) in the mersilene mesh group developed dermatochalasis after six months and underwent surgery for creation of a lid crease. The latter cases belonged to the same patient. Pre- and postoperative photographs of representative patients from each group are shown in figures 2 and 3.

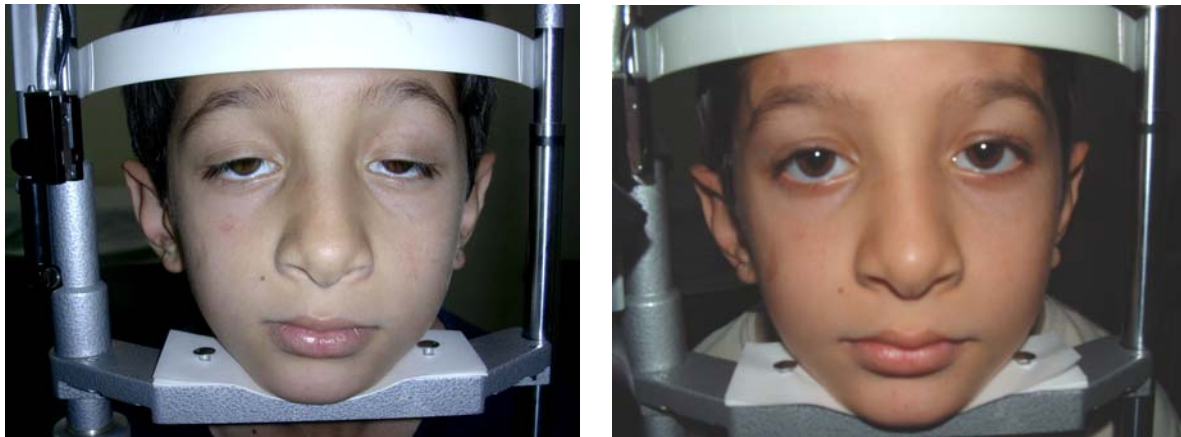

Figure 2 A patient with bilateral blepharoptosis before (left) and after (right) mersilene mesh sling procedure.

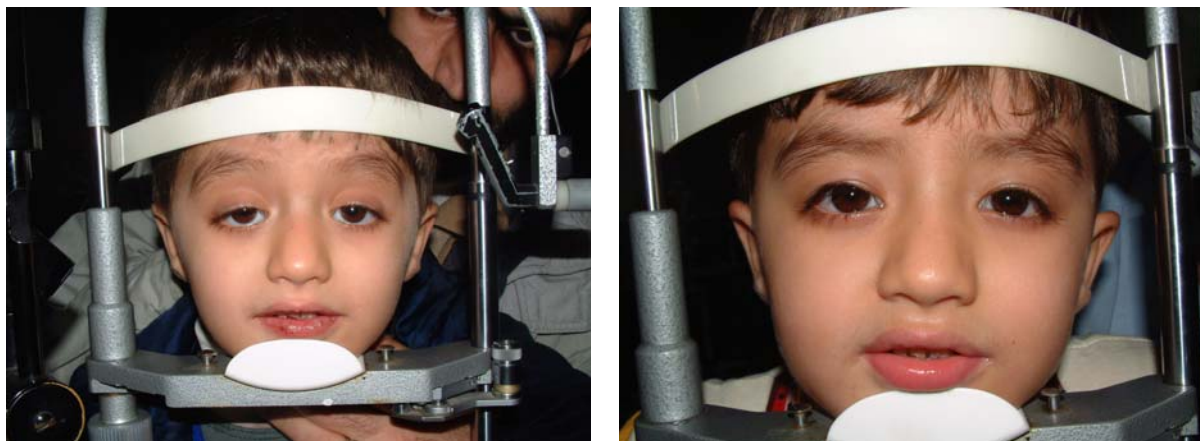


Figure 3 A patient with bilateral blepharoptosis before (left) and after (right) fascia lata sling procedure.

DISCUSSION

Blepharoptosis surgery, a challenging area in oculoplastic surgery, is mainly aimed to improve the appearance by producing symmetric lid crease and position in the upper lids. Certain cases of congenital blepharoptosis or acquired blepharoptosis in the first decade of life which occlude the visual axis need urgent intervention to prevent amblyopia. The frontalis suspension procedure is the classic approach in cases of blepharoptosis with weak levator function, especially in congenital or acquired myogenic and neurogenic ptosis. In this procedure, frontalis power is transferred to the upper lid by connecting the frontalis muscle to the tarsus using natural or synthetic mate-

rials. There are different methods and materials for this procedure but most surgeons believe that autogenous fascia lata is the best choice followed by banked fascia. Common methods of slinging include single rhomboid, double rhomboid and double triangular.¹⁻³

Autogenous fascia lata cannot be used in certain cases such as children less than 3 years of age (due to inadequate length), in the presence of extensive scars in the region precluding harvest of adequate fascia and in circumstances when temporary correction of ptosis (e.g. ptosis secondary to hemangiomas in neonates) is indicated. Other circumstances where fascia lata may be inappropriate include severe dry eye, lack of adequate Bell's phenomenon and decreased corneal sensation; under these

circumstances elastic materials such as silicone which allow eyelid closure may be preferable.¹⁻³ Other materials used for slinging include silk, stainless steel, prolene, collagen, umbilical vein, catgut, mersilene mesh, tantalum, sclera, supramid and skin. Although most of these materials are readily available, low-priced and easily applicable, they are not recommended due to the high rates of short- and long-term complications such as cheese wiring, stretching, fragmentation and infection. None of these materials has proven to be as safe and efficacious as fascia lata.⁴⁻¹⁹

Mersilene mesh (polyester fibers), a readily available, low-priced material with high tensile strength, has recently been used in brow suspension procedures. It functions as a scaffold for growth of fibrovascular tissue. Mersilene mesh has provided acceptable long-term stability for ptosis correction according to previous studies.⁴⁻¹¹ Long-term results of mersilene mesh and autogenous fascia lata have been comparable in three previous studies.²⁰⁻²² The long-term success rate of mersilene mesh in ptosis correction has been reported from 77% to 94.4%.⁴⁻¹¹ In the present study, only one case in the mersilene mesh group developed an under-correction of 1 mm at final follow-up and other cases had stable lid fissures. The upper lid margins and eyelid fissures were symmetric and comparable in both groups with no significant difference in terms of lid fissure height or MRD-1 increase. Our results are consistent with similar studies.²⁰⁻²²

Mersilene mesh extrusion and granuloma formation at the brow skin incision site have been reported to be due to thinness of the overlying soft tissue and thickness of the mesh. Most of these cases need surgical intervention for removal of excess mesh, skin repair and control of infection. Regardless of surgical technique, the risk of granuloma formation and mesh extrusion due to tissue reaction to mersilene exists; however this risk may be decreased by meticulous skin repair and completely burying the mesh under the frontalis muscle.²³⁻²⁵ We encountered two cases of mersilene mesh extrusion in our series within two

weeks after the operation which were successfully repaired.

In the current series, 10 eyelids (66.7%) in the fascia lata group versus 2 (12.5%) in the mersilene mesh group developed dermatochalasis necessitating blepharoplasty and creation of an eyelid crease. The reason for this difference may be smaller volume of material in the mersilene mesh group compared to fascia lata. The patient who underwent blepharoplasty in the mersilene mesh group was 42 years old and probably had preexisting dermatochalasis which was exaggerated following surgery.

According to the present study, the long-term stability of mersilene mesh sling procedure is comparable with that of fascia lata suspension which is consistent with previous reports. Moreover, mersilene mesh entails certain advantages over fascia lata such as the possibility of using local anesthesia, less bulky material, better cosmetic results, less need for additional corrective procedures, avoiding the scar of a large incision in another part of the body, shorter surgical time and faster post-operative recovery.

In conclusion, mersilene mesh suspension may be the preferable method in young children and recommended in any case of ptosis with weak levator function, even if autogenous fascia lata suspension is possible. Complications such as granuloma formation and mesh extrusion may not adversely affect the final outcome and may be prevented by adhering to a meticulous surgical technique.

REFERENCES

1. Landa M, Bedrossian Jr EH. Blepharoptosis, ophthalmic plastic surgery, decision making and techniques. McGraw-Hill Companies; 2002: 77-89.
2. Ellis FD, Ellis FJ. Correction of blepharoptosis in children. In: Duane's ophthalmology. 2005: Chap. 104, CD-ROM edition.
3. Bosniak SL, Smith BC. Advances in ophthalmic and reconstructive surgery. 1st ed. New York: Pergamon Press; 1982.
4. Downes RN, Collin JRO. The Mersilene mesh sling—a new concept in ptosis surgery. *Br J Ophthalmol* 1989;73:498-501.

5. Downes RN, Collin RJ. The Mersilene mesh ptosis sling. *Eye* 1990;4:456-463.
6. Can I, Can B, Yarangumeli A, Inan Y, Kural G. Ptosis surgery using Mersilene mesh suspensory material. *Eur J Ophthalmol* 1996;6:150-154.
7. Gabrieli CB, Recupero SM, Contestabile MT, Pacella Elena, Abdolrahimzadeh S. Fox' modified technique using the Mersilene mesh sling in the management of blepharoptosis. *Ophthalmic Surg Lasers* 1996;27:924-928 .
8. Lam DSC, Gandhi SR, Ng JS, Chen IN, Kwok PS, Chan GH. Early correction of severe unilateral infant ptosis with the Mersilene mesh sling. *Eye* 1997;11(pt.6):806-809.
9. Mehta P, Patel P, Oliver JM. Management of Mersilene mesh chronic eyelid complications: a systematic approach. *Eye* 2004;18:640-642.
10. Sharma TK, Willshaw H. Longterm follow up of ptosis correction using Mersilene mesh. *Eye* 2003;17:759-761.
11. Hintschich CR, Zurcher M, Collin JR. Mersilene mesh brow suspension: efficacy and complications. *Br J Ophthalmol* 1995;79:358-361.
12. Broughton WL, Matthews JG, Harris Jr DJ .Congenital ptosis, results of treatment using lyophilized fascia lata for frontalis suspensions. *Ophthalmology* 1982;89:1261-1266 .
13. Sternberg I, Seelenfreund MH, Sternberg N. A new sling material for ptosis patients. *Ophthalmic Surg* 1988;19:64-66.
14. Carter SR, Meecham WJ, Seiff SR. Silicone Frontalis Slings for the correction of blepharoptosis. *Ophthalmology* 1996;103:623-630.
15. Esmail B, Chung H, Pashby RC. Long-term results of frontalis suspension using irradiated, banked fascia lata. *Ophthal Plast Reconstr Surg* 1998;14:159-163.
16. Kokot W, Polijanoski P. Suspending of blepharoptosis on temporalis fascia slings: our own experience. *Klin Oczna* 1998;100:393-395.[Abstract]
17. Betharia SM. Frontalis sling: a modified simple technique. *Br J Ophthalmol* 1985;69:443-445.
18. Katowitz JA. Frontalis suspension in congenital ptosis using a polyfilament, cable-type suture. *Arch Ophthalmol* 1979;97:1659-1663.
19. Lam DS, Lam TP, Chen IN, Tsang GH, Gandhi SR. Palmaris longus tendon as a new autogenous material for frontalis suspension surgery in adult. *Eye* 1996;10(pt.1):38-42.
20. EL-Toukhy E, Salaem MEL, Shewy T, Abou-Steit M, Lrine M. Mersilene mesh sling as an alternative to autogenous fascia lata in the management of ptosis. *Eye* 2001;15(pt.2):178-182.
21. Elder MJ. Mersilene mesh and fascia lata in brow suspension: a comparative study. *Ophthalmic Surg* 1993;24:105-108.
22. Kemp EG, MacAndie K. Mersilene mesh as an alternative to autogenous fascia lata in brow suspension. *Ophthal Plast Reconstr Surg* 2001;17:419-422.
23. Mutla FM, Tuncer K, Can C. Extrusion and granuloma formation with Mersilene mesh brow suspension. *Ophthalmic Surg Laser* 1999;30:47-51.
24. Mehta P, Patel P, Oliver JM. Management of mersilene mesh chronic eyelid complication: a systematic approach. *Eye* 2004;18:640-642.
25. Mehta P, Patel P, Oliver JM. Functional results and complications of mersilene mesh use for frontalis suspension ptosis surgery. *Br J Ophthalmol* 2004;88:361-364.